



## Comparative analysis of final inclination of incisors after space closure. A comparison between sliding and translation mechanical techniques

### *Análisis comparativo de la inclinación final de los incisivos después del cierre de espacios entre mecánicas de deslizamiento y traslación*

Aracely Cumba Morán,\* Roberto Ruiz Díaz,§ Arcelia Meléndez Ocampo<sup>||</sup>

#### ABSTRACT

Patients will undoubtedly benefit when having teeth well placed in all space planes, within their bone base. Therefore, in many cases, teeth extractions become necessary. The aim of the present study was to determine whether there were statistically significant differences in tooth movement, specifically in the anterior segment of the mouth, when comparing mechanical translation and sliding mechanical techniques. Sixty lateral skull x-rays were selected. Study groups were formed: 30 were subject to translation mechanical technique, and the remaining 30 to sliding technique. Measurements were taken by the same professional. Variable averages were compared before and after treatment, to determine the existence of statistically significant differences. Final measurements with both space closure techniques were compared. Results showed the presence of statistically significant differences in the translation technique with respect to variables (overjet, overbite, IMPA, II-NB, 1-SN, 1-Fh) before and after treatment. This was not the case for the following variables (1S-NA, occlusal 1-PI, interincisal angle). It was equally observed that in the sliding mechanical technique there were statistically significant differences found in the variable II-NB). This was not the case for the other variables (overbite, overjet, 1S-NA, 1Sn, 1Fh, 1-Ocl. PI. LIMA, Inter-incisive A). We therefore beg to conclude that translation mechanical technique is the one that brings us closer to cephalometric data norms with respect to final position of the incisors.

**Key words:** Incisor position, cephalometric changes.

**Palabras clave:** Posición incisal, cambios cefalométricos.

#### INTRODUCTION

In order to achieve proper orthodontic treatment it is necessary to have, from the very onset, a clear definition of desired goals, in such a manner as to decide upon which devices to put into use. Treatment

#### RESUMEN

Dejar al diente bien ubicado en todos los planos del espacio; dentro de su base ósea, será sin duda alguna un beneficio saludable para el paciente, por lo que las extracciones de piezas dentarias en la mayoría de los casos se hacen necesarias. El objetivo de este estudio es determinar si existen diferencias estadísticamente significativas en el movimiento dentario específicamente del segmento anterior entre las mecánicas de traslación y deslizamiento. Se seleccionaron 60 radiografías laterales de cráneo. Se formaron dos grupos de estudio, 30 fueron sometidos a mecánica de traslación y 30 a deslizamiento. Las mediciones fueron realizadas por un mismo profesional calibrado. Se compararon los promedios de las variables, antes y después del tratamiento en cada una de las mecánicas para determinar si existían diferencias estadísticamente significativas y se compararon las mediciones finales entre una y otra mecánica de cierre de espacios. Los resultados demostraron que entre la mecánica de traslación sí hubo diferencias estadísticamente significativas entre las variables (overjet, overbite, IMPA, II-NB, 1-SN, 1-Fh) antes y después del tratamiento no así en las variables (1S-NA, 1-PI.Oclusal, ángulo interincisal). De igual manera se observó que en la mecánica de deslizamiento se presentaron diferencias estadísticamente, encontradas en la variable (II-NB) y no en las variables (overbite, overjet, 1S-NA, 1-SN, 1-Fh, 1-PI.Ocl., IMPA, A. Interincisal). Al comparar las mediciones finales de cada una de las mecánicas, los resultados demostraron que no hubo diferencias estadísticamente en: (overbite, overjet, 1S-Na, II-Nb, 1-SN, 1Fh, 1-PI.Ocl., IMPA, ángulo interincisal). Con esto concluimos que con la mecánica de traslación, nos acercamos más a la norma de los datos cefalométricos en la posición final de los incisivos.

\* Graduate, Orthodontics Department, Graduate School.

§ Professor attached to the Orthodontics Department, Graduate School.

<sup>||</sup> Graduate School professor, Dentistry and Public Health Department Coordinator.

National School of Dentistry, National University of Mexico (UNAM).

This article can be read in its full version in the following page: <http://www.medigraphic.com/facultadodontologiaunam>

will have to meet proposed objectives, so as to finally restore comprehensive oral health in the patient with respect to all aspects: esthetics, periodontal health, stability and function.<sup>1</sup>

One of the goals to be achieved is a well placed tooth in all spatial angles within its bone base. This will undoubtedly constitute a healthy benefit for the patient.<sup>2,4,5</sup>

Final position achieved by every tooth, especially anterior teeth, within its bone base is indispensable and fundamental to achieve stability, masticatory function, harmony and facial balance as a final result.<sup>2</sup>

A proper relation between upper and lower incisors inclination helps us to adequately admeasure occlusal forces on an ideal anterior guide.

Lower incisive pro-inclination procedures have been used in certain cases to increase vertical dimension of lower incisor over upper incisor and thus obtain a more suitable anterior guide. This anterior guide is integrated by incisor and canine guides, and performs a prominent function in any stomatological scope. These guides are essential for proper phonation and mastication functions, they also have a functional role in protecting posterior teeth during jaw movements.<sup>3</sup>

The position of the teeth will impact on soft tissues. Therefore, after having completed orthodontic treatment, the patient must be able to exhibit facial profile harmony.<sup>4</sup>

Cephalometric analysis encompasses determination of incisor position.<sup>2</sup>

There are several proposed norms to describe lower and upper incisor position. These standards have been used to predict the stability of treatment results. Nevertheless, this position also involves axial inclination of the remaining incisor, and therefore, its impact on the stability, relapse, and facial esthetics.<sup>5</sup>

The aim of the present study was to achieve an assessment of incisor position changes in the following space-closing mechanical procedures: translation and sliding. This could provide valuable information for treatment planning.

## MATERIALS AND METHODS

Sixty lateral cephalograms were analyzed after orthodontic treatment of patients selected from the files of the Orthodontics Department of the Graduate School, National School of Dentistry, National University of Mexico. Cases were selected from years 2000-2005.

Selected x-rays concerned patients whose treatment had included extraction of first upper and lower premolars. These patients were also lacking any history of craniofacial anomalies or dental illness. Cephalo-

metric x-rays were taken according to standard methods. To avoid errors, one single researcher traced them on acetate paper. They were divided according to the retraction mechanical technique followed, that is, either translation or sliding. Metric measurement was employed. Points, reference lines and measurements used in this study were as follows:

Reference points: Porion (Po), Orbitare (Or), Nasion (Na), point A, point B, Chin (Ch), Gonion (Go), Gnathion (Gn) lower incisor (Mn1), upper incisor (Mx1), Sella (S).

Angle measurements: Inter-incisor angle, SN angle upper incisor, upper incisor Fh occlusal plane-lower incisor, Lower Incisor mandibular angle (LIMA).

Linear measurements: vertical overbite, horizontal overbite, upper incisor and N-A line, lower incisor and N-B line.

Four linear and five angular measurements were used to assess changes in longitudinal growth of incisor position, as well as horizontal and vertical overbite. 20 cases were selected and re-traced to determine method error.

Repeated measurements were examined with *t*-test. *T* (*student*) test was applied to determine whether cases were homogenous between both mechanical procedures to close spaces.

## SAMPLE SELECTION CRITERIA

Inclusion: clinical cases with complete records. Skull lateral x-rays of clinical cases having initiated and completed treatment at the Orthodontics Department of this Graduate School. Clinical cases of lateral skull x-rays of orthodontic treatment onset and completion. Clinical cases of incomplete permanent dentition. Clinical cases of mixed dentition. Clinical cases of primary dentition.

Exclusion was made of clinical cases with deteriorated or poor skull lateral x-rays. Clinical cases lacking initial lateral skull x-rays. Clinical cases presenting initial or final x-rays not taken at the Graduate School of the National School of Dentistry, National University of Mexico.

## METHODS FOR GATHERING INFORMATION

X-rays were taken following standard methods. Orthodontic treatments with 4 premolar extraction were selected.

Skull lateral x-rays were classified according to each orthodontics philosophy followed at the orthodontics

department of the Graduate School, National School of Dentistry, National University of Mexico. Trends included were the following: MBT, Tip-edge, Roth, Ricketts bio-progressive, zero degrees, Alexander.

These trends were divided according to their space-closure mechanical procedures into sliding and translation, thus, 30 for each procedure were obtained. Angular and linear measurements have already been described.

**RECORDING AND PROCEDURE METHODS**

For each mechanical procedure, standard deviations were calculated on a yearly basis.

Variance was used to assess space-closure effects of each mechanical procedure. Incisor inclination as well as horizontal and vertical overbite were also appraised in this manner.

All data were recorded in a cephalometric data summary specifically developed for this study and incorporated to the appropriate file. Results from gathered data were analyzed in an Excel database. They were exported to the SSPS Windows statistical package for further analysis.

**RESULTS**

For each variable, paired samples were analyzed to describe tracings relationships of both initial and final x-rays (T test, average, standard deviation and standard error average).

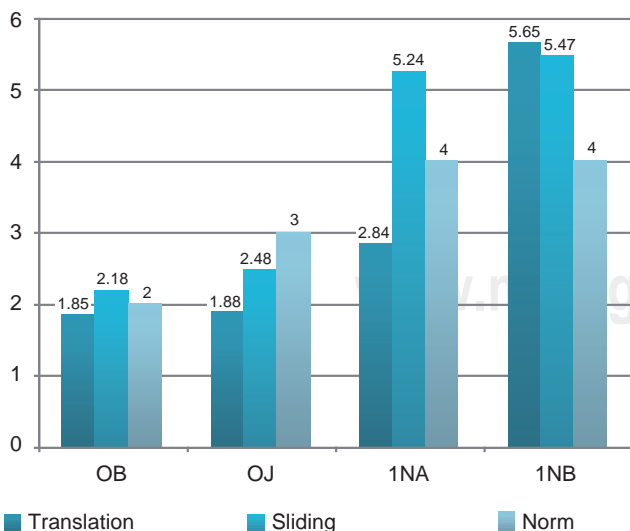
For each variable, paired sample test analyses were conducted on relationships of average differences between both x-rays (average, standard deviation, with 95% confidence interval).

Results showed that, in translation mechanical procedure, there were statistically significant differences among variables (overbite, inter-incisor angle) before and after treatment. In the following variables there was no statistically significant difference: overjet, 1S-NA, II-NB, 1-Fh, 1-SN,1-Occl. PI. LIMA).

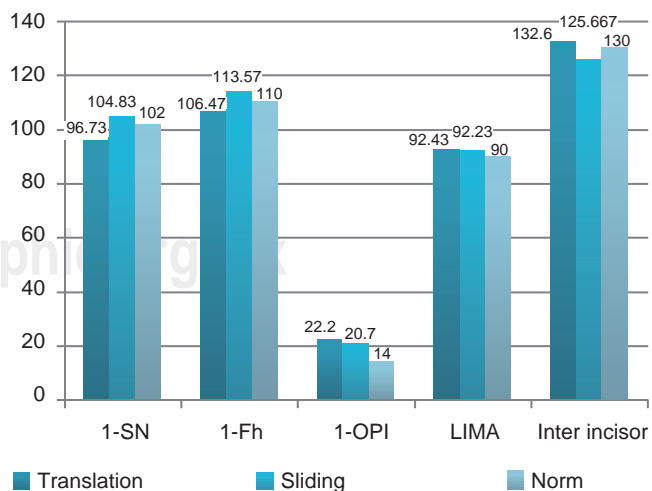
In sliding mechanical procedure the following was observed: statistically significant differences found in variable (A. inter-incisor, overbite). In the following variables there were no statistically significant differences: (overbite, overjet, II-NB, 1S-NA, 1-SN,1-Fh,1-Ocl.PI, LIMA).

When comparing final measurements of each variable in both procedures, results showed there were no statistically significant differences in the variables (Figures 1 and 2) (II-Nb. 1-Ocl.PI LIMA, Inter-incisor angle) ( $p > 0.05$ , and there were statistically significant differences among variables (overjet, overbite, 1-Fh. 1Na, 1-SN )  $p < 0.05$ .

Results of this study showed that, in orthodontic treatments, there were statistically significant differences in incisors final position after space closure depending on the mechanical procedure used (translation or sliding). Results also showed the need not to leave incisors in an excessive vertical position so as to avoid tendency towards relapse and functional instability.



**Figure 1.** Linear measure comparison between both space closure mechanical techniques.



**Figure 2.** Angular measure comparison between both space closure mechanical techniques.

## DISCUSSION

When comparing final measurements of each variable in every mechanical procedure, results showed there were no statistically significant differences in variables (II-Nb, 1-Ocl-PI, LIMA inter-incisor angle ( $p > 0.05$ )). Notwithstanding, there were statistically significant differences in the following variables: overjet, overbite, 1-Fh, 1-Na, 1-SN ( $p < 0.05$ ).

The present study found statistically significant differences between both techniques of mechanical space closure.

This study found that with the translation space closure technique, the position of incisors was closer to cephalometric norms established through the years. This favors future occlusion stability since an anterior guide is achieved. This has a beneficial effect on the patient. These results highlight Alonso's<sup>6</sup> reports, where he states that anterior crowding and lingual inclination of lower incisors could elicit, not only unpleasing esthetic results which could give way to functional alterations, but could also have an effect on de-occlusion mechanisms. Inclination of teeth towards the palate cause constraints in a defective occlusion; this generates restrictive areas in eccentric movements.<sup>6</sup> The aforementioned reports are in agreement with the present paper.

Forsberg and Behrens informed that upper incisors became, in both genders, more vertical with the passing of time. Forsberg also found that lower incisors in males, presented greater trend towards pro-inclination. Nevertheless, in both genders, he did not find changes in the inter-incisor angle. This agrees with our results where it is considered appropriate to leave teeth within their bone base to avoid future relapses, since, in most cases, orthodontic treatment is normally conducted upon youthful patients, still in growing phases.

Behrens did not find changes in the inter-incisor angle in females. Nevertheless, he did find a decrease in this same angle in male patients.

Neither of both authors found changes in vertical overbite. This agrees with our analysis with respect to changes in overbites. In this we found no significant changes. Nevertheless, this study does not agree with Sinclair and Little, who informed that horizontal and vertical overbite significantly increased in patients aged 9-13 years. These changes tend to decrease in patients aged 13-20 years.

This study shows statistically significant changes in both retraction mechanical procedures in the following: horizontal and vertical overbite, FH-upper incisor, 1-Na and 1-SN. We therefore beg to propose that achieving final proper position for incisors after orthodontic treat-

ment is advisable so as to ensure future functional stability along with anterior and canine guide.

## CONCLUSIONS

The present study showed statistically significant changes in axial inclination and position of lower and upper incisors with respect to different retraction mechanical procedures.

Cephalometric measurements obtained through lateral skull x-rays, have become one of the most important factors to consider when emitting a diagnosis in patients afflicted with dental and skeletal anomalies. Nevertheless, final dental position of incisors must be borne in mind, since it is going to have repercussions in soft tissues, and to achieve proper functional occlusion. Therefore, this dental position, after orthodontic treatment should, in the patient, achieve harmony in facial profile as well as proper function.

We finally beg to conclude that, according to gathered cephalometric data, in orthodontic treatment, when using translation mechanical procedure, greater tooth stability was achieved. This situation is closer to the norm.

## REFERENCES

1. Burstone C. *Modern edgewise mechanics segmented arch technique*. Ormco corporation 1989.
2. Ceylan I, Baydas B, Bölükbaşı B. Longitudinal cephalometric changes in incisor position, overjet, and overbite between 10 and 14 years of age. *Angle Orthod* 2002; 72: 246-250.
3. Linda J. Anterior guidance: Group function/canine guidance. A literature review. *J Prosthet Dent* 1990; 64: 479-482.
4. Gjessing P. Controlled retraction of maxillary incisors. *Am J Orthod Dentofacial Orthop* 1992; 101: 120-131.
5. Williams R. The diagnostic line. *Am J Orthodontics* 1969; 55 (5): 458-476.
6. Alonso A. *Oclusión y diagnóstico en rehabilitación oral*. Ed. Médico Panamericana S.A. Argentina 2000.

## RECOMMENDED LITERATURE

1. Choy K. Controlled space closure with a statically determinate retraction system. *Angle Orthod* 2002; 72: 191-198.
2. Burstone CH. The segment arch approach to space closure. *Am J Orthod* 1982; 85: 361-378.
3. Geron S. Vertical forces in labial and lingual orthodontics applied on maxillary incisors – A theoretical approach. *Angle Orthod* 2004; 74: 195-201.
4. Kazem S. Changes in mandibular incisor position in Class II division 1 malocclusion treated with premolar extractions. *Am J Orthod Dentofacial Orthop* 2003; 124: 708-713.
5. Boley J. Long-term stability of Class I premolar extraction treatment. *Am J Orthod Dentofacial Orthop* 2003; 124: 277-287.
6. Uribe F. Treatment of Class II division 2 malocclusion in adults: biomechanical considerations. *J Clin Orthod* 2003; 37 (11): 599-606.
7. Ghahferokhi AE. Critical assessment of a device to measure incisor crown inclination. *Am J Orthod Dentofacial Orthop* 2002; 121 (2): 185-191.

8. Minagi S. Relationship between anterior guidance and mesiodistal inclination of lower incisor in human subject with or without TMJ noise. *J Oral Rehabil* 1999; 26 (10): 781-5.
9. O'Higgins EA. The influence of maxillary incisor inclination on arch length. *Br J Orthod* 1999; 26 (2): 97-102.
10. Güray E. "En masse" retraction of maxillary anterior teeth with anterior headgear. *Am J Orthod Dentofacial Orthop* 1997; 112: 473-479.
11. Melsen B. Vertical force considerations in differential space closure. *J Clin Orthod* 1990; 24 (11): 678-683.
12. Bulcke M. Location of the centers of resistance for anterior teeth during retraction using the laser reflection technique. *Am J Orthod Dentofacial Orthop* 1987; 91: 375-384.
13. Dawson PE. *Evaluation, diagnosis and treatment of occlusal problems*. 2 ed St Louis: CV Mosby, 1989.

Mailing address:  
**Aracely Cumba Morán**  
E-mail: aritacumba@yahoo.com