



## Electronic work length with Raypex 6 in lower molars canals

### *Longitud de trabajo electrónica con Raypex 6 en conductos de molares inferiores*

Norberto J Broom,<sup>\*,§</sup> Álvaro Cruz,<sup>§,||</sup> Claudia A Palafox-Sánchez,<sup>||</sup>  
Rocío Stefany Padilla Delgado,<sup>||</sup> Analí Torres Camarena<sup>||</sup>

#### ABSTRACT

**Objective:** To assess precision of Raypex 6 to locate foramen and establish placement in the canal -dentin-cement (CDC) area in lower molar canals by means of diaphanization. **Material and methods:** 52 permeable canals from 20 extracted lower molars immersed in alginate were used. Crown opening, location, permeabilization and irrigation with 5.25% sodium hypochlorite were performed. Electronic conductometry was obtained with Raypex 6 electronic locator. A K #15/20 file type was inserted in all samples which had labial clip inserted in alginate. The device's screen indicated position of the apical foramen in the red bar, K files position was readjusted in the first two yellow bars, the file was then fixated with acrylic resin. Teeth were diaphanized by means of the nitric acid technique; teeth were kept in methyl salicylate. Samples were analyzed with clinical microscope at 16x, they were subjectively assigned a value called precise when the tip of the file was located at 0-0.5 mm, external or positive (+), when the file was +0.1 mm or more, and short or negative (-) when it was -0.51 mm or less with respect to the apical foramen. **Results:** Of the 52 analyzed samples, 40 were found to be precise, seven long and five short. Descriptive statistics showed 76.9% precision. **Conclusion:** Electronic working length with Raypex 6 showed suitable precision in mesial canals of lower molars.

**Key words:** Working length, Raypex 6, endodontics.

**Palabras clave:** Longitud de trabajo, Raypex 6, endodoncia.

#### INTRODUCTION

Precise location of the apical foramen and determination of conductometry is one of the most important phases of endodontic treatment, due to the fact that it is the space where instrument use and filling of root canals are limited.<sup>1</sup> The target is to ensure that root canal treatment is conducted within anatomical limits of the root canal.<sup>2</sup>

Periapical X-rays are used to conventionally obtain working length, nevertheless it has been shown it suffers limitations during execution. From a subjective interpretation it can be said that anatomical structure superposition, image distortion, quality of film and/or sensor affect the image, hindering observation of apical foramen position; it is a bi-dimensional

#### RESUMEN

**Objetivo:** Evaluar la precisión de Raypex 6 para localizar el foramen y ubicarse en la zona cemento-dentina conducto (CDC) en conductos de molares inferiores por medio de diafanización. **Materiales y métodos:** 52 conductos permeables de 20 molares inferiores extraídos inmersos en alginato fueron utilizados. Se realizó apertura coronaria, localización, permeabilización e irrigación con hipoclorito de sodio al 5.25%. Con el localizador electrónico Raypex 6 se obtuvo conductometría electrónica. Se introdujo lima tipo K #15 o 20 en cada muestra que tenía el clip labial inserto en alginato. La pantalla del dispositivo indicó la posición del foramen apical en la barra roja y se procedió a reajustar la posición de la lima K en las dos primeras barras amarillas y la lima se fijó con resina acrílica. Los dientes se diafanizaron por medio de la técnica de ácido nítrico y se mantuvieron en salicilato de metilo. Las muestras se analizaron con microscopio clínico a 16x y de manera subjetiva se asignó el valor de preciso, si la punta de la lima se ubicó entre 0 a -0.5 mm, fuera o positivo (+) si la lima estuvo +0.1 mm o más y corto o negativo (-) si fue de -0.51 mm o menos con respecto al foramen apical. **Resultados:** De las 52 muestras analizadas, se encontraron 40 precisas, siete largas y cinco cortas. La estadística descriptiva demostró 76.9% de precisión. **Conclusión:** La longitud de trabajo electrónica con Raypex 6 mostró una adecuada precisión en conductos mesiales de molares inferiores.

\* Professor, Graduate Degree of Endodontics, Centro Universitario de los Altos (los Altos University Center).

§ Private practice in Endodontics.

|| Biomedical Sciences Research Institute, Professor at the Endodontics Program.

¶ DDS Graduate.

University Center for Health Sciences, University of Guadalajara, Guadalajara, Mexico.

Received: August 2017.

Accepted: November 2017.

© 2018 Universidad Nacional Autónoma de México, [Facultad de Odontología]. This is an open access article under the CC BY-NC-ND license (<http://creativecommons.org/licenses/by-nc-nd/4.0/>).

This article can be read in its full version in the following page: <http://www.medigraphic.com/facultadodontologiaunam>

image of a three-dimensional object. Moreover complications might rise when treating patients with nauseous reflex, affected with macroglossia, or are pregnant women or children.<sup>3</sup>

Electronic working length was first proposed by Custer<sup>4</sup> in 1918, under the principle of electric conductivity.<sup>3</sup> With these principles in mind, Suzuki<sup>5</sup> in 1942, reported that electric resistance of an instrument within instrumented root canal and connected to an electrode applied to the oral mucosa, recorded constant values.<sup>6,7</sup>

With these values, in 1962, Sunada<sup>8</sup> developed a simple locator of continuous current to measure root canal. With time, locators were designed, using impedance in simple or multiple frequencies having overcome problems encountered by the first locators.<sup>9</sup> Presently, fourth generation devices use two separate frequencies (400 HZ and 8 kHz) which measure resistance of two alternate currents (AC) frequencies at the same time, and thus impedance coefficient is obtained.<sup>3</sup>

It has been shown that fourth generation locators are not affected by the presence of irrigating solutions in the canal,<sup>6</sup> nevertheless, the reason for erroneous measurements could be due to certain morphological aspects such as lateral, accessory or convergent canals, resorptions, perforations and contact with metals.<sup>10</sup> A combination of techniques is advisable in order to achieve more accurate working length during endodontic treatment.<sup>3,11-13</sup> Nevertheless, in clinical situations where endodontic treatment was performed, due to the fact one patient was wearing postsurgical retention plate, and another had been subjected to orthodontic treatment involving a maxillary expander, it was observed that LEF were effective for electronic conductometry, using two X-rays.<sup>14</sup> Another study reported five endodontic treatments performed with exclusively electronic conductometry; it was observed that 12 out of 14 endodontic treatments were at a distance of 0-2 mm from the radiographic apex, thus showing that electronic working length is a reliable method which decreases the number of trans-operative X-rays.<sup>15</sup>

Based on the aforementioned, the purpose of this project was to evaluate accuracy of Raypex 6 to locate foramen and locate in the area of CDC (cement-dentin-canal) in canals of lower molars.

## MATERIAL AND METHODS

For the study, 52 canals from 20 extracted, lower molars were used, provided by the tooth file of the Specialties' Maxillofacial Surgery Service, Military

Regional Hospital of Guadalajara, Jalisco, in order to conduct electronic measurements with a Raypex 6 device (VSW Munich, Germany). With a diamond disk (SS White-Mexico) clinical crowns were cut in all the molars at the cement enamel junction. Samples were individualized into mesial and vestibular roots. Roots were diagonally cut with respect to the longitudinal axis in order to obtain a flat border with the axis of the tooth's root and thus achieve access with direct vision into the root canal. Canals were located with DG16 explorer (SS White-USA), and were permeabilized with a K file numbers 10 and 15 (VDW GmbH, Germany). Canal entrances were irrigated with 5.25 sodium hypochlorite (Viarzonit-T Mexico), they were broadened in the cervical third with Gataes-Glidden number 4 burr (VDW GmbH, Germany) Roots (in their middle and apical thirds) were placed in a vertical position in a glass containing alginate (Tropicalgin-Zhermack, Mexico City), to replicate natural oral humidity. Measurements were conducted on the flat surface, following at all times manufacturer's recommendations.

The crown was accessed with a number 4, high speed, round burr (Jet SDS Kerr-Mexico City), canal location and permeabilization was conducted with type K file, number 8 or 10 (VDW GmbH, Germany). Irrigation was performed with 5.25% sodium hypochlorite (Viarzoni T, Mexico City). With clip inserted in alginate (mark) a number 15 or 20 type K file was introduced (VDW GmbH), in accordance with the file that did fit, assessed by means of tactile sensation and apparent measurement in the X-ray. Screen of Raypex 6 device (VDW Munich, Germany) indicated the position of the apical foramen in the red bar. K file was then readjusted (VDW GmbH, Germany) in the first two yellow bars. It was reserved for 10 seconds until reading was stabilized, the K file (VDW GmbH Germany) holder was removed and was fixated to the tooth with acrylic resin. With foramen locator, reading was once more verified. Teeth were diaphanized with nitric acid technique, and were then preserved in methyl salicylate. Pictures were obtained with clinical microscope OPMI 1 FR PRO (Zeiss Mexico) at 16x as well as with a digital camera (Sony, Japan). Digital images were obtained which were then evaluated by two endodontic specialists, blinded and calibrated to identify the limit of the apical foramen; a subjective value was assigned: accurate when the tip of the file was at 0 to 0.5 mm, external or positive (+) when the file was  $\pm 0.1$  mm or more, and short or negative (-) when it was at -0.5 mm or less with respect to the apical foramen. No samples were excluded in the present study.

**RESULTS**

In the present study, with conducted observations and applied descriptive statistics, 40 precise working lengths were found, representing 76.9% and 12 non-precise working lengths, representing 23.1%. Non-precise conductometries were seven external (13.5%) and five short (9.6%) with respect to the apical foramen (Figures 1 to 3).

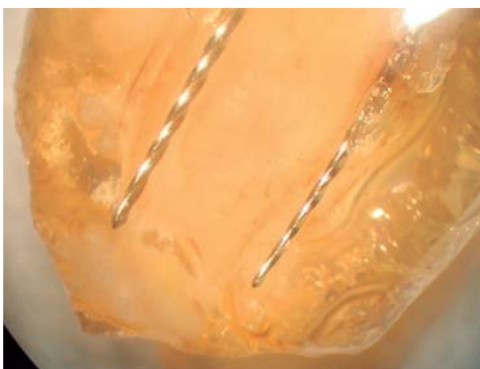
**DISCUSSION**

Root canal systems are limited by apical foramen,<sup>16-19</sup> nevertheless, the apical foramen does not have a point as a limit, that is to say, this anatomical region is called area or junction of cement-dentin-canal (CDC), and is thus defined as CDC zone and not CDC limit. Due to anatomical variability of apical foramen, CDC junction can be found at an average 1-2 mm from the apical foramen.<sup>3</sup> In an X-ray, CDC area is generally located at 1-1.5 mm short of the radiographic apex, nevertheless, this length can vary<sup>3</sup> due to the fact that it is impossible to establish with an x ray the exact position of the CDC zone.<sup>2,20</sup>


When endodontic treatment is undertaken, it is of the utmost importance to accurately establish position of the CDC zone, since it bears influence in the repair

of periapical tissues,<sup>19</sup> therefore accurate working length must be secured. Some research papers report that electronic and radiographic methods present similar results,<sup>13,21,22</sup> nevertheless, LEFs have the advantage that their reference point is the apical foramen, which is imperceptible in X-rays.<sup>20</sup> The radiographic method has the radiographic apex as a reference point, which, in most cases differs from the location of the main foramen.<sup>23</sup>

Precision of the devices Root ZX, Raypex 5 and Elements Apex Locator was assessed in order to locate the minor foramen as well as morphological factors which influence in the determination of the working length; and they considered that morphology of the minor foramen and its position are factors which directly influence in the LEFs precision,<sup>24</sup> and that apical resorptions in teeth with apical periodontitis similarly bear some influence.<sup>15</sup> The present work employed recently extracted teeth and did not consider whether there were or weren't apical resorptions. Raypex 6 was reliable in 76.9%. In another *in vivo* study, which compared Raypex 5, DentaPort ZX



**Figure 1.** Precise working length in mesial canals.



**Figure 2.** Working length outside of the apical foramen and distal canal.



**Figure 3.** Short working length in mesial canals.

and ProPex II, it was concluded they did not exhibit differences in major foramen location.<sup>24</sup>

Raypex 6 is a fourth generation device, manufactured by the company VDW (Germany), it was available in the market in June 2011.<sup>25</sup> LEFs of this generation separately measure resistance and capacitance they have double frequency (400 Hz and 8 kHz) and are controlled by a microprocessor which is used to determine working length.<sup>3,26</sup> In the first work reported in literature (2014), a comparison was established between Raypex 6 and DentaPort ZX in 36 patients' single rooted teeth. A number 10 file was placed in each canal and was fixated with light-cured resin. The apical portion of the root was exposed, and the distance from the tip of the file to the apical foramen was measured. No significant difference was found between DentaPort ZX and Raypex 6 in terms of ability to detect main foramen. DentaPort ZX was accurate in 82.3% in the  $\pm 0.5$  mm and 97% in  $\pm 1$  mm, whereas Raypex 6 was accurate in 88.2% in the  $\pm 0.5$  mm range and 100% in the  $\pm 1$  mm;<sup>27</sup> these figures are higher than those found in the present study which revealed 76.9% accuracy.

Differences between Raypex 5 and Raypex 6 are related to the device, that is to say, with the model and not the operating principle, according to the McDonald et al classification,<sup>28</sup> both are fourth generation devices. With reliability presently offered by LEFs,<sup>13,29-32</sup> it is possible to propose performance of root canals system treatment with two and three X-rays.<sup>13-15</sup> Nevertheless, to this date, there are still no 100% reliable and accurate LEFs,<sup>3</sup> that is to say, we still have to resort to X-rays; even a combination of methods could be considered as ideal.<sup>3</sup> In the present work with Raypex 6, inaccuracy of 23.1% was encountered.

Raypex 6 is an electronic device in which, according to the manufacturer, the position of the CSDC zone is located between green and yellow stripes,<sup>25</sup> this is to say it does not directly show the precise position of the CDC junction, therefore, in the present study CDC junction was considered when in the Raypex 6 screen it was shown to be in the two yellow bars, which indicated that the file is at a 0.5 distance from the apical foramen. From the aforementioned, at that same position a 62.5% incertitude was obtained with Raypex 6, which suggests it is a non-precise, unreliable LEF for electronic conductometry. Nevertheless it must be worthwhile to mention that a rigorist working length criterion was used, assessed with scanning electron microscopy.<sup>33</sup> This varies when a clinical criterion is applied, that is to say, observation and assessment through X-rays. In a report of five root canal treatment

performed exclusively with electronic working length (without radiographic confirmation), and only two X-rays, it was observed that the obturation level in 12 out of 14 canals was found to be from 0 to 2 mm of the radiographic apex. It is considered that the electronic working length is reliable and decreases treatment time and number of X-rays.

With used methodology, Somma et al study<sup>34</sup> was considered reliable. In this study three LEF were compared *in vivo* (DentaPort ZX, Raypex 5 and Propex II); they used diaphanization to evaluate samples, and found that according to *in vivo* circumstances, all three LEFs did not show statistically significant differences among them with respect of apical foramen location. Even though in our study a 76.9% precision was obtained with Raypex 6, with this methodology it is considered that during the de-mineralization process undertaken for diaphanization, there could be loss of apical root tooth structure, as well as a possible alteration in electronic measurements, perhaps this was the reason for the 23.1% non-precision rate of Raypex 6.

In another study, Raypex 6 precision to locate CDC zone and main foramen was evaluated with the use of cone beam computerized tomography (CBCT), in dry circumstances, or when irrigated with sodium hypochlorite, bi-distilled water or Ultracain; 150 extracted human teeth were divided into five groups (n = 30). Positive and negative values were recorded as short and long working length. Electronic measurements were more reliable than those observed with CBCT. Raypex 6 was more precise to locate main foramen when compared to CDC.<sup>35</sup> Briefly, use of Raypex 6 to determine working length does not fully avoid the risk of overestimating measurements outside of the apical foramen.

## CONCLUSION

Bearing in mind limitation inherent to the *in vitro* study, it can be said that Raypex 6 was accurate in 76.9%, and can be used with limitations and anatomical considerations in the endodontic clinic, therefore, it is recommended to conduct further clinical studies with this device and to replicate the reality observed in the endodontic clinic.

## REFERENCES

1. Stoll R, Urban-Klein B, Roggendorf MJ, Jablonski-Momeni A, Strauch K, Frankenberger R. Effectiveness of four electronic apex locators to determine distance from the apical foramen. *Int Endod J.* 2010; 43 (9): 808-817.
2. Ramos CAS, Bramante CM. *Odontometria fundamentos e técnicas.* São Paulo, Brasil: Ed. Santos; 2005.

3. Gordon MP, Chandler NP. Electronic apex locators. *Int Endod J*. 2004; 37 (7): 425-437.
4. Custer LE. Exact methods of locating the apical foramen. *J Natl Dent Assoc*. 1918; 5: 815-819.
5. Suzuki K. Experimental study of iontoforesis. *Japanese J Stomatol*. 1942; 16: 411-429.
6. Jenkins JA, Walker WA 3rd, Schindler WG, Flores CM. An *in vitro* evaluation of the accuracy of the root ZX in the presence of various irrigants. *J Endod*. 2001; 27 (3): 209-211.
7. Hembrough JH, Weine FS, Pisano JV, Eskoz N. Accuracy of an electronic apex locator: a clinical evaluation in maxillary molars. *J Endod*. 1993; 19 (5): 242-246.
8. Sunada I. New method for measuring the length of the root canal. *J Dent Res*. 1962; 41: 375-387.
9. Fan W, Fan B, Gutmann JL, Bian Z, Fan MW. Evaluation of the accuracy of three electronic apex locators using glass tubules. *Int Endod J*. 2006; 39 (2): 127-135.
10. Briseño MB. *Consideraciones clínicas para evitar y corregir errores durante la preparación del conducto radicular*. In: Cruz-González A, Vera-Rojas J, Lara-Rosano A, Briseño-Marroquín B, Betancourt-Lozano E. *Endodoncia: fundamentos científicos para la práctica clínica*. México: Amateditorial; 2012. pp. 103-146.
11. Cianconi L, Angotti V, Felici R, Conte G, Mancini M. Accuracy of three electronic apex locators compared with digital radiography: an *ex vivo* study. *J Endod*. 2010; 36 (12): 2003-2007.
12. Wrbas KT, Ziegler AA, Altenburger MJ, Schirmeister JF. *In vivo* comparison of working length determination with two electronic apex locators. *Int Endod J*. 2007; 40 (2): 133-138.
13. Ravanshad S, Adl A, Anvar J. Effect of working length measurement by electronic apex locator or radiography on the adequacy of final working length: a randomized clinical trial. *J Endod*. 2010; 36 (11): 1753-1756.
14. Machado R, Tomazinho LF, Azedo-Stel AM, Leal-Silva EJN, Pascoal-Vansan L. Use of electronic apex locator in the impossibility of radiographic visualization of the root apex: report of two cases. *RSBO*. 2013; 10 (4): 402-406.
15. Broon NJ, Cruz A, Palafox-Sanchez CA, Andaracua-García S, García-Hervert RB, Ayón-García R. Root canal treatment with electronic conductometry without radiographic trans-operative verification: report of five cases. *Dental Press Endod*. 2015; 5 (1): 73-77.
16. Grove CJ. Why canals should be filled to the dentino cemental junction. *J Am Dent Assoc*. 1930; 17: 293-296.
17. Kuttler Y. Microscopic investigation of root apices. *J Am Dent Assoc*. 1955; 50 (5): 544-552.
18. Dummer PM, McGinn JH, Rees DG. The position and topography of the apical canal constriction and apical foramen. *Int Endod J*. 1984; 17 (4): 192-198.
19. Ricucci D, Langeland K. Apical limit of root canal instrumentation and obturation, part 2. A histological study. *Int Endod J*. 1998; 31 (6): 394-409.
20. Jakobson SJ, Westphalen VP, da Silva Neto UX, Fariniuk LF, Picoli F, Carneiro E. The accuracy in the control of the apical extent of rotary canal instrumentation using Root ZX II and ProTaper instruments: an *in vivo* study. *J Endod*. 2008; 34 (11): 1342-1345.
21. Williams CB, Joyce AP, Roberts S. A comparison between *in vivo* radiographic working length determination and measurement after extraction. *J Endod*. 2006; 32 (7): 624-627.
22. Renner D, Grazziotin-Soares R, Gavini G, Barletta FB. Influence of pulp condition on the accuracy of an electronic foramen locator in posterior teeth: an *in vivo* study. *Braz Oral Res*. 2012; 26 (2): 106-111.
23. Saito T, Yamashita Y. Electronic determination of root canal length by newly developed measuring device. Influences of the diameter of apical foramen, the size of K-file and the root canal irrigants. *Dent Jpn (Tokyo)*. 1990; 27 (1): 65-72.
24. Ding J, Gutmann JL, Fan B, Lu Y, Chen H. Investigation of apex locators and related morphological factors. *J Endod*. 2010; 36 (8): 1399-1403.
25. Manual Raypex 6. *Manual de instrucciones*. VDW. Munich, Alemania: 2011. pp. 108-132.
26. Broon NJ, Cruz A, Palafox-Sánchez C, Andaracua-García S. Principios, evolución y precisión de los localizadores electrónicos de foramen. *Rev Endod Actual*. 2015; 10 (3): 14-27.
27. Moscoso S, Pineda K, Basilio J, Alvarado C, Roig M, Duran-Sindreu F. Evaluation of Dentaport ZX and Raypex 6 electronic apex locators: an *in vivo* study. *Med Oral Patol Oral Cir Bucal*. 2014; 19 (2): e202-e205.
28. McDonald NJ. The electronic determination of working length. *Dent Clin North Am*. 1992; 36 (2): 293-307.
29. Stöber EK, Duran-Sindreu F, Mercadé M, Vera J, Bueno R, Roig M. An evaluation of root ZX and iPex apex locators: an *in vivo* study. *J Endod*. 2011; 37 (5): 608-610.
30. Stöber EK, de Ribot J, Mercadé M, Vera J, Bueno R, Roig M et al. Evaluation of the Raypex 5 and the Mini Apex Locator: an *in vivo* study. *J Endod*. 2011; 37 (10): 1349-1352.
31. Piasecki L, Carneiro E, Fariniuk LF, Westphalen VP, Fiorentin MA, da Silva Neto UX. Accuracy of Root ZX II in locating foramen in teeth with apical periodontitis: an *in vivo* study. *J Endod*. 2011; 37 (9): 1213-1216.
32. Duran-Sindreu F, Stöber E, Mercadé M, Vera J, Garcia M, Bueno R et al. Comparison of *in vivo* and *in vitro* readings when testing the accuracy of the Root ZX apex locator. *J Endod*. 2012; 38 (2): 236-239.
33. Juárez-Broon N. Comparación *in vivo* de tres localizadores electrónicos de foramen en dientes con periodontitis apical [Tesis de Doctorado]. Guadalajara, Jalisco: Universidad de Guadalajara; 2015.
34. Somma F, Castagnola R, Lajolo C, Paternò-Holtzman L, Marigo L. *In vivo* accuracy of three electronic root canal length measurement devices: Dentaport ZX, Raypex 5 and ProPex II. *Int Endod J*. 2012; 45 (6): 552-556.
35. Lucena C, López JM, Martín JA, Robles V, González-Rodríguez MP. Accuracy of working length measurement: electronic apex locator versus cone-beam computed tomography. *Int Endod J*. 2014; 47 (3): 246-256.

Mailing address:

**Norberto J Broon**

E-mail: endobr1@hotmail.com

**Álvaro Cruz. DDS, MS, PhD.**

E-mail: endoacruz@yahoo.com